

SLIT-LAMP IMAGING: EXAM THROUGH EXECUTION

SPONSORED BY

HS HAAG-STREIT
DIAGNOSTICS



Images produced at the slit lamp are worth a thousand words.

BY MICHAEL E. SNYDER, MD

I am fascinated by the versatility of slit-lamp imaging. The stunning images that slit-lamp photography produces can be crucial components in the clinical management of our patients. They help us to identify unique ocular anatomy and to document the progressive changes in pathophysiology over time. In a nutshell, slit-lamp images are worth a thousand words.

Quality slit-lamp images are an integral part of devising a safe and effective treatment plan for a variety of select anterior segment pathologies, and they are an equally crucial part of our follow-up exams. In this article, I share three cases in which exquisite slit-lamp images were helpful to me in planning and executing surgery in a complex situation and in documenting the postoperative outcome and improvement seen in these patients throughout their follow-ups.

CASE PRESENTATIONS

► **Case No. 1: Eye with a small pupil.** An 82-year-old woman with a history



Figure 1. Slit-lamp image of the eye of an 82-year-old woman with a history of chronic anterior uveitis and a very tiny pupil (left). The image was taken with Haag-Streit's BQ 900 (right).



of chronic anterior uveitis that was suppressed on prednisolone BID presented with a BCVA of 20/80-1 and complaints of very poor and dark vision. The patient had a very tiny pupil (150 μ m). The biggest challenges for slit-lamp examination in the presence of a small pupil like this patient's are inadequate light for a good image, limited contrast and diffraction from the edges of the pupil, and a limited view of the fundus. But with the BQ 900 (Haag-Streit), I could see the reflection off the front surface of the implant lens (Figure 1). The relative visual potential of this eye was unclear given the inability to visualize the posterior segment.

In the OR, I placed a 27-gauge anterior chamber maintainer and used a 27-gauge vitrector to sculpt the iris. I prefer the 27-gauge to 25- or 23-gauge vitrectors because it sculpts very slowly. I have also found that the smaller gauge avoids too much iris tissue from rolling away with any given bite. With the 27-gauge vitrector in the anterior chamber, I started to sculpt at the original pupil, but because the pupil margin was a little too fibrotic, I quickly moved to another area. I used low vacuum and a relatively low cut rate, and my goal was to create a pupil about 3.5 mm in size, as I expected that it might get smaller again over time.

I like to both add preservative-free dexamethasone to the

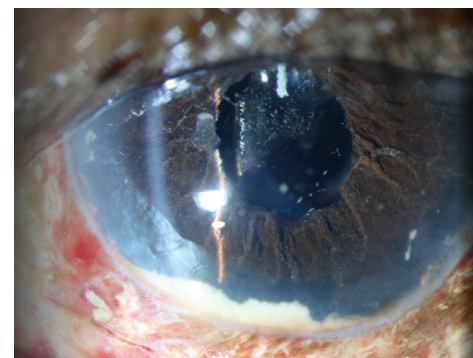


Figure 2. The same eye as Figure 1: On postoperative day 1, the well-formed pupil is visible, along with tiny triamcinolone crystals.

balanced saline solution infusion and finish the case with an injection of dilute 1:10 preservative-free triamcinolone (Triescence, Alcon) into the anterior chamber, which I have found helps to keep the eye quiet. In eyes with chronic uveitis, I am extra cautious about keeping inflammation under tight control. After hydrating the wound at the end of surgery, the eye was white and quiet.

On postoperative day 1, the patient's UCVA was 20/60 and pinhole to 20/25+1. The patient was ecstatic with her outcome. In the slit-lamp image in Figure 2, the well-formed pupil is visible, as well as some tiny triamcinolone crystals, which will disappear with time.

► **Case No. 2: The unhappy photographer and pilot.** A 53-year-old man who is an avid astronomy photographer and a recreational aircraft pilot presented 3 weeks after cataract surgery with the chief complaint of seeing a shadow move back and forth in his vision. Figure 3

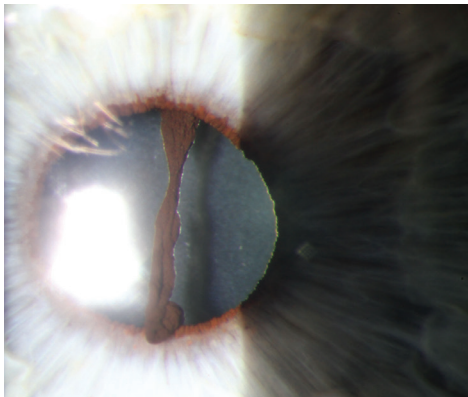


Figure 3. Slit-lamp image with the BX 900 (Haag-Streit) of the eye of a 53-year-old man with a clear cornea, nice red reflex, and a well-positioned IOL.

shows his slit-lamp examination with the BX 900 (Haag-Streit). The cornea is clear, there is a nice red reflex, and the IOL is well positioned; however, when enlarged in the dilated state, a piece of iris dangling in the middle of the pupil is visible (Figure 4).




Figure 4. The same eye as Figure 3: When the slit-lamp image is enlarged in the dilated state, a piece of iris dangling in the middle of the pupil is visible (left and right).

You could imagine how this would be bothersome, especially because of the patient's visually high-demanding hobbies. With the optics of the BX 900 slit-lamp photo, I was able to identify the dangling piece of iris and, subsequently, remedy the patient's visual complaints by removing the offending fragment.

► **Case No. 3: Two different patients with conjunctival intraepithelial neoplasia (CIN).**

Being able to see and document disease progression or response to treatment is especially important in complex cases. Figure 5 shows an eye with clinical features of CIN, including abnormal elevation, keratinization, enlarged feeder vessels, and avascular limbal pannus. After topical chemotherapy and monitoring of the patient with slit-lamp images, the clinical features had improved (Figure 6). By the patient's final visit, the lesion had completely disappeared. In this patient with a particularly aggressive tumor, I used images from the BQ 900 (Haag-Streit) to document how nonsurgical treatment of helped this eye to stay clear for 10 years.

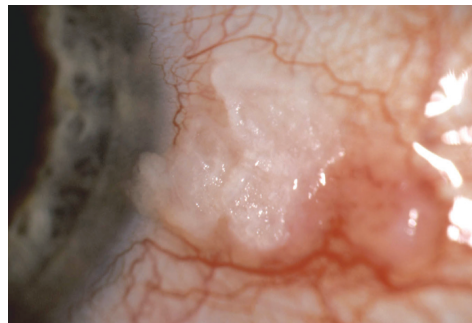


Figure 5. BQ 900 (Haag-Streit) slit-lamp image of an eye with clinical features of CIN.

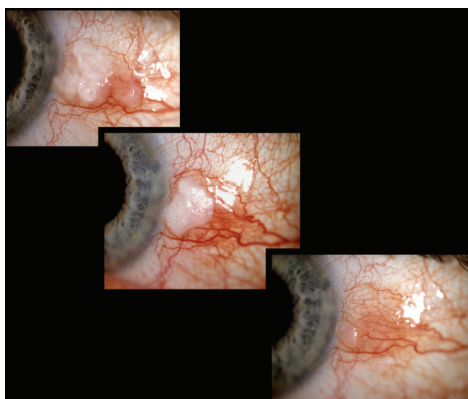


Figure 6. The same eye as Figure 5: After topical chemotherapy and monitoring of the patient with slit-lamp images, the clinical features of CIN had improved.

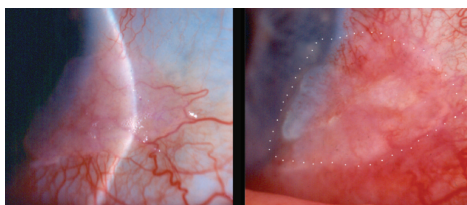


Figure 7. Slit-lamp images from another patient with clinical features of CIN helped Dr. Snyder document that the lesion had enlarged.

In another patient with clinical features of CIN, topical mitomycin C therapy was initiated, but the patient developed surface toxicity at 56 days. After a 1-week break from the treatment, the patient's lesion had enlarged (Figure 7); without these slit-lamp images, I might not have been able to identify the subtle growth of the lesion, on treatment, had I been relying on written notes alone. Excision with cryotherapy was subsequently performed. Having photographic documentation of the progression really did change how I treated this patient and, ultimately, aided in the successful outcome.

CONCLUSION

Being able to photograph the eye is very important. In all cases, it aids in our treatment planning and in many cases it helps us to document the success of our treatments. Further, slit-lamp images are especially invaluable in complex cases, as they can be used to help us hone our treatments and pivot to a new plan when necessary. ■

MICHAEL E. SNYDER, MD

- Board of Clinical Governance, Cincinnati Eye Institute, Cincinnati, Ohio
- Associate Professor of Ophthalmology—Affiliated, University of Cincinnati, Ohio
- Chair, Clinical Research Steering Committee
- Msnyder@cincinnatieye.com
- Financial disclosure: Consultant (Haag-Streit USA, HumanOptics, W.L. Gore & Associates); Clinical investigator and royalties (HumanOptics); Shareholder (VEO Ophthalmics); Research (Alcon, Bausch + Lomb, Johnson & Johnson Vision, Glaukos)